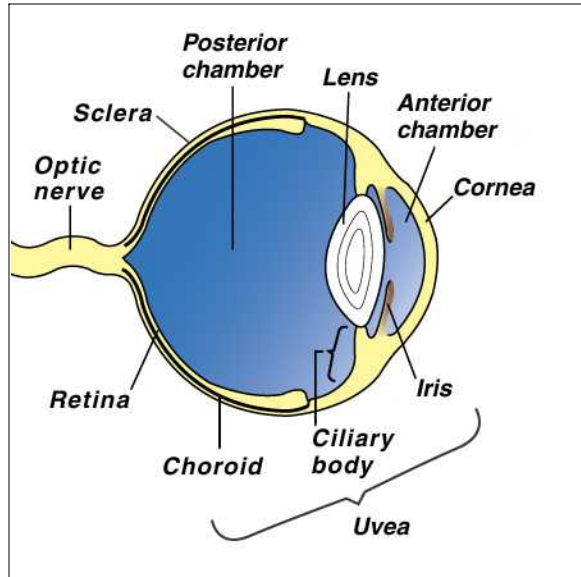


UVEITIS

The *uvea* comprises the iris, the ciliary body and the choroid within the eye. The choroid is the middle or vascular tunic or coat of the eye between the sclera – the fibrous protective outer coat (the white of the eye) -- and the retina which is the light sensitive surface within the eye.



The iris and the ciliary body together form the anterior uveal tract. The iris is the pigmented membrane behind the cornea (clear part of the eye). It is responsible for the color of the eye. The size of the central perforation or pupil controls the amount of light entering the eye. The ciliary body is a thickened extension of the choroid (vascular tunic of the eye) and connects the choroid and the iris. It produces the aqueous humor important in nutrition of the eye and also in maintaining intra-ocular pressure (IOP). The ciliary body contains muscles and the suspensory ligament supporting the lens within the eye. The ciliary muscles via the suspensory ligament control the shape of the lens and hence its ability to focus images.

Uveitis has a variety of synonyms. If all three structures are involved, ciliary body, iris and choroid, it is true uveitis or *pan-uveitis*. If only the ciliary body and the iris are inflamed it is called *iridocyclitis* or *anterior uveitis*, while inflammation of the choroid is *choroiditis* or *posterior uveitis*.

What causes uveitis?

There are many potential causes of uveitis. Sometimes the true cause is never discovered. Common causes are:

- Infection - viral, bacterial, parasitic or fungal
- Metabolic disease
- Diabetes mellitus
- High blood pressure
- Toxemia
- Immune mediated - particularly autoimmune disease where the dog produces antibodies against its own tissues
- Trauma to the eye
- Lens damage resulting in the leakage of lens protein, and tumors

What are the clinical signs of uveitis?

The usual signs of uveitis are severe pain with an intense reddening of the visible parts of the eye. The eye is usually kept shut and most pets avoid bright lights. Cloudiness of the eye may be noticed. Sometimes there is bleeding into the eye. There may be excessive tearing.

How is uveitis diagnosed?

Many of the signs of uveitis are similar to glaucoma. With uveitis, IOP is reduced whereas with glaucoma it is elevated. Measurement of IOP is often performed to differentiate between the two conditions and is a simple, painless procedure. A complete and thorough physical examination of the pet must be performed since generalized illnesses can have uveitis as one of their signs. Often there is a color change of the iris, which may remain permanent. Special procedures such as ultrasound may be used to examine the eye.

What is the treatment of uveitis?

Treatment is initially aimed at reducing inflammation and providing pain relief. Treatment of uveitis due to trauma can involve repair of any corneal tears or removal of a foreign body in the eye. This may involve referral to a specialist. A combination of drops or ointments combined with tablets may be required.

In order to assess the initial response to treatment, your veterinarian will need to examine your dog frequently.

What is the prognosis of uveitis?

Most cases of uveitis begin to improve within twenty-four hours. If the eye is very cloudy or if hemorrhage has occurred, this may take a few more days to clear.

Complications are more common after very severe or repeated cases of uveitis. These can involve the development of synechiae and glaucoma. Synechiae are adhesions between the lens and the iris. Glaucoma is an increase in IOP. Both complications may need specialist treatment. Severe uveitis can result in irreversible blindness.